



Mandibular evidence supports *Homo floresiensis* as a distinct species

Henneberg et al. (1) and Eckhardt et al. (2) present another pathology-based alternative to the hypothesis that the “hobbit” fossils from Liang Bua, Indonesia, represent a distinct hominin species, *Homo floresiensis*. They contend that the Liang Bua specimens are the remains of small-bodied humans and that the noteworthy features of the most complete specimen, LB1, are a consequence of Down syndrome (DS). Here, we show that the available mandibular evidence does not support these claims.

Absence of chins in the two mandibles recovered at Liang Bua, LB1 and LB6, is a key issue (1, 3). That these specimens lack chins has been argued to preclude their attribution to *Homo sapiens*, because a chin is widely accepted to be a defining characteristic of our species (3). Henneberg et al. reject this argument on the grounds that a chin is often absent in living Australo-Melanesians. However, the evidence they present does not support their assertion regarding Australo-Melanesian mandibular morphology. One of two studies they cite has not been peer reviewed (the publication is just a conference abstract), whereas the other one has been severely criticized (4). Henneberg et al. also imply that a mandible from Roonka, Australia, supports their claim, but a CT scan of this specimen shows that it has a positive chin (Fig. 1). Thus, there is no reason to believe that living Australo-Melanesians often lack chins and therefore no reason to overturn Brown and Tomoko’s (3) assessment that the absence of chins in LB1 and LB6 precludes their attribution to *H. sapiens*.

Henneberg et al. (1) and Eckhardt et al. (2) choose not to mention a number of other traits shared by the LB1 and LB6 mandibles that are also inconsistent with attribution to *H. sapiens*. Fig. 1 presents a CT scan of the LB1 mandible. It is obvious from this that, as has been pointed out previously (3), LB1 exhibits internal buttressing of the mandibular symphysis. This trait, which is also seen in LB6 (3), appears in earlier *Homo* but not *H. sapiens*. LB1 and LB6 also exhibit a strong extramolar sulcus, a trait found in early hominins but not *H. sapiens* (3). Additionally, LB1’s and LB6’s tooth root morphology differs from that seen in *H. sapiens* (3). DS cannot explain the presence of these traits in LB1 and LB6. Researchers who have studied modern people diagnosed with DS have not found these traits to be among the mandibular and dental features of DS (5, 6). Additionally, LB6 is accepted to be a normal individual by all researchers, including Eckhardt et al. (p. 11963 in ref. 2). Therefore, the only reasonable interpretation of the traits is that they are part of the normal biology of the population to which LB1 and LB6 belong. That LB1 and LB6 share the traits with early hominins but not *H. sapiens* refutes Henneberg et al.’s hypothesis.

Many interesting questions about the Liang Bua fossils remain unanswered, but whether LB1 is a pathological *H. sapiens* is not one of them. As we have demonstrated, the available mandibular evidence is already sufficient to discount this possibility.

Michael Carrington Westaway^{a,1}, Arthur C. Durband^b, Colin P. Groves^c, and Mark Collard^{d,e}

^a*Environmental Futures Research Institute, Griffith University, Brisbane, QLD 4111, Australia;* ^b*Anthropology Department, Texas Tech University, Lubbock, TX 79409-1012;* ^c*School of Archaeology and Anthropology, Australian National University, Canberra, ACT 2601, Australia;* ^d*Department of Archaeology, Simon Fraser University, Vancouver, BC, Canada V5A 1S6; and* ^e*School of Geosciences, University of Aberdeen, Aberdeen AB24 3UE, United Kingdom*

1 Henneberg M, Eckhardt RB, Chavanaves S, Hsü KJ (2014) Evolved developmental homeostasis disturbed in LB1 from Flores, Indonesia, denotes Down syndrome and not diagnostic traits of the invalid species *Homo floresiensis*. *Proc Natl Acad Sci USA* 111(33):11967–11972.

2 Eckhardt RB, Henneberg M, Weller AS, Hsü KJ (2014) Rare events in earth history include the LB1 human skeleton from Flores, Indonesia, as a developmental singularity, not a unique taxon. *Proc Natl Acad Sci USA* 111(33):11961–11966.

3 Brown P, Maeda T (2009) Liang Bua *Homo floresiensis* mandibles and mandibular teeth: A contribution to the comparative morphology of a new hominin species. *J Hum Evol* 57(5):571–596.

4 Fitzpatrick SM, Nelson GC, Clark G (2008) Small scattered fragments do not a dwarf make: Biological and archaeological data indicate that prehistoric inhabitants of Palau were normal sized. *PLoS ONE* 3(8):e3015.

5 Sanderson A, Laycock PJ, MacCulloch MM, Girling A (1975) Morphological jaw differences in mentally subnormal and normal adult males. *J Biosoc Sci* 7(4):393–410.

6 Rivollat M, Castex D, Hauret L, Tillier A-M (2014) Ancient Down syndrome: An osteological case from Saint-Jean-des-Vignes, northeastern France, from the 5–6th century AD. *Int J Paleopathol* 7:8–14.

Author contributions: M.C.W., A.C.D., C.P.G., and M.C. wrote the paper.

The authors declare no conflict of interest.

¹To whom correspondence should be addressed. Email: m.westaway@griffith.edu.au.

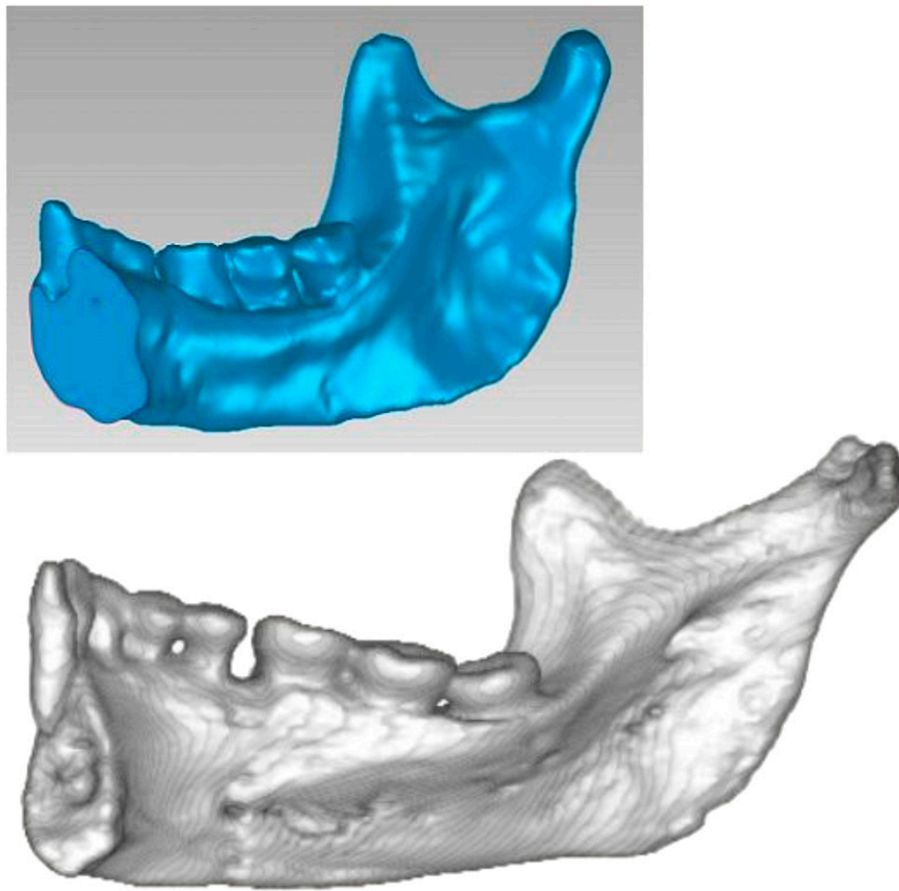


Fig. 1. CT scans of the Liang Bua 1 mandible (*Upper*) and an Aboriginal Australian *Homo sapiens* mandible, Roonka 45 (*Lower*). The distinct internal buttressing of the symphysis that can be seen in LB1 is found in early hominins but not *Homo sapiens*. Both mandibles are to scale.